

---

## The Impact of the Glucocorticoid Hormones on the Mucosal Mast Cells

Salha A. Zoubi,\* Rabeea Elmatmati,\*

---

### Abstract:

The small intestinal mucosal mast cells (MMC) distribution in the villi and the crypts of certain rodents, in addition to their response to the treatment with steroid hormones (glucocorticoids) is examined on Wistar, male rats which received a daily dose of prednisolone injection. The results were consistent in control animals with the previous findings showing larger mucosal mast cell population around the crypts than in the villous lamina propria throughout the small intestinal tract declining distally in both normal and treated rats. Prednisolone treated rats showed that the numbers of MMC were lower as compared to the normal counts after 24hrs and close to the normal values after 48 hrs of drug induction, tending to be higher after 72 hrs. The short period and low dose of the drug induction, although it suppresses the MMC counts, the MMC structure and function were not significantly affected as these numbers were shortly replaced. The intestinal lamina propria may overcome the periods of decreased activities through different physiologic processes.

Key Words: Prednisolone; Mucosal Mast Cells; rat intestine.

---

### Introduction:

This project is concerned with a glucocorticoid synthetic hormone (Prednisolone) and its effects on a distinctive cell category which is the mucosal mast cells (MMCs) of rats. The MMCs are the mast cells located in the vicinity of blood vessels in the lamina propria of the mucosa of the mammalian gastrointestinal tract lining villi and surrounding crypts.<sup>1</sup> MMC granules contain chondroitin sulfate instead of heparin in the connective tissue mast cells. The two types of cells also react differently to pharmacologic agents and contain numerous granules which can be demonstrated by special staining methods, as the glycosaminoglycan content of these granules is relatively of low molecular weight,<sup>2</sup> and though they are coupled with protein and they can easily be dissolved in routinely used fixatives and therefore its visualization requires the application of an appropriate fixative and staining procedures.<sup>3</sup> Extensive studies revealed several effects of glucocorticoids on certain components of the immune response. Prednisolone which is one of these steroids is found to have an immunosuppressive effect on lymphocyte proliferation.<sup>4,5</sup> This study is aiming to give an overview of these cells and their response to the prednisolone injection along the intestinal tract of rats.

The glucocorticoid are synthesized by the cells of zona fasciculata and zona reticularis and released into the circulation under the

influence of ACTH, and are removed from the circulation in liver, where it is reduced and conjugated to form water-soluble compounds that are excreted into the urine. Steroids bind to specific intracellular receptors upon entering target tissues having widespread effects because they influence the function of mast cells in the body. The major metabolic consequences of glucocorticoid secretion or administration are due to the direct action of these hormones on the cells. They also have important dose-related effects on carbohydrate, protein, and fat metabolism. The same effects are responsible for some of the serious adverse effects associated with their use in therapeutic doses.

The catabolic effects of the glucocorticoids on lymphoid and connective tissue, muscle, fat, and skin may lead to decreased muscle mass and weakness, osteoporosis, reduce growth and constitute a major limitation in the long-term therapeutic use of glucocorticoids although they have the capacity to dramatically reduce the manifestations of inflammation.

The general effects of the drug have been widely studied by many workers but their impression on the numerical density of the mucosal cells in the rat small intestine has not been reported. It was decided to re-investigate the numerical density of the mucosal mast cells in villi and around crypts with special reference to the effect of prednisolone.

---

\*) Anatomy and Biochemistry Departments, Faculty of Medicine, Garyounis University, Benghazi, Libya.

### Experimental:

A total number of 9 adult male wistar rats weighing 200-250 gm. were used, six animals comprised the test group and the rest of animal were control group. The animals were kept in day light between 6.00am to 18.00pm, otherwise in the darkness. The ambient temperature is 20c. water and standard diet pellets were provided .

Prednisolone is given to the animals of test groups as intramuscular injections (0.5mg daily dose). The injections were usually given between 9am and 11pm. which continued for one week.

The control animals were injected with normal saline according to the same schedule. The animals were sacrificed at 24, 48 & 72 hours after the last dose of drug induction.

The small intestine was divided into three segments. Pieces from the three intestinal portions were taken and histologically processed.

### Histological procedure:

Specimens of intestinal fragments (each is 1-2cm long) were fixed in methanol-formalin-glacial acetic acid (85:10:5) mixture, dehydrated and embedded in paraffin and cut at 10µm thick sections. These sections after deparaffinization were stained with toluidine blue (pH 1.0) counterstained with acid fuchsin\mordant method<sup>3,6</sup> to stain the granules of mast cells for mast cell counts.

The light microscope was utilized to identify and study the general distribution of mast cells in intestinal mucosa.

### Stereological procedure;

The method of stereology described for ultra thin sections was adopted for the light microscopic level. For all measurements, the graticule consisting of 100 squares was placed into the eyepiece of the microscope. Using the immersion objective, 100x and eye piece 10x the graticule surface area was calculated as 1451.6µm. All measurements were done by placing the graticule on a section image and recording the numbers of intersections of graticule points with

1- the mast cell(Pm); the sections of mast cells with clear nuclei were exclusively taken into consideration.

2- fragments of connective tissues of lamina propria (Pc) of either villi or that surrounding the crypts. The volumetric density (Vv) ie the fraction of volume of mast cell to the volume of tissue which surrounds the mast cells

(connective tissue of lamina propria) was estimated from the fraction

$$Pp = Pm / Pc \text{ (for lamina propria mast cell)}$$

Adapting the basic stereological equation:

$$Vv = Pp$$

From these equations the volumetric density Vv of either lamina propria mast cells of villi or those of the lamina propria surrounding the crypts were calculated and expressed as the fractions

The surface density Sv of mast cells was calculated from the formula

$$Sv = m/PS$$

Where m = number of mast cell profiles (each containing nucleus) per counted field

PS = number of intersection points of fragments of mucosal connective tissue expressed in square micrometers of the graticule.

Surface density of mast cell therefore represents the number of their profiles per unit of surface area e.g square millimeter. The numerical density Nv of mast cells was calculated according to the formula

$$Nv = k/b \times \text{square root of } NA/Vv$$

Where NA = number of profiles of mast cells per tested area

K = size distribution coefficient of the mast cells which is estimated as about 1.2

B = shape coefficient of mucosal mast cells estimated as about 2.5

Vv = volumetric density of mast cells per cubic unit of connective tissue of lamina propria.

All parameters obtained at present ie Vv ,Sv, Nv of mast cells were calculated separately for sections of three segments of the small intestine as well as for lamina propria of villi and that surrounding the crypts.

More than 6000 fields of mucosa from at least 100 villi and around 100 crypts were analysed in both control and the three groups of Prednisolone treated rats.

### Results and Discussion:

Mast cells were observed after the application of appropriate fixation and staining in the villous lamina propria & around the crypts along the intestinal tract of control and treated rats. These cells were identified by dark blue colour of their cytoplasmic granules stained with toluidine blue at pH 1.0 and by red round nucleus stained with acid fuchsin.

The general appearance of mast cells in the villi and around the crypts were similar to each other.

The stereological analysis of test fields in more than 100 villi and crypts revealed the numerical density in the target cells which were calculated in the villi and around the crypts of both control and treated rats after 24, 48 & 72 hours.

In control animals, the numbers of the mast cells around the crypts were higher than those of the villous mast cells, in addition, mast cells were decreasing toward the distal intestinal segments in both villi and crypts. The differences between the calculated parameters of various parts of lamina propria and various regions of intestine was significant at 0.05 level of confidence. It is relevant that the

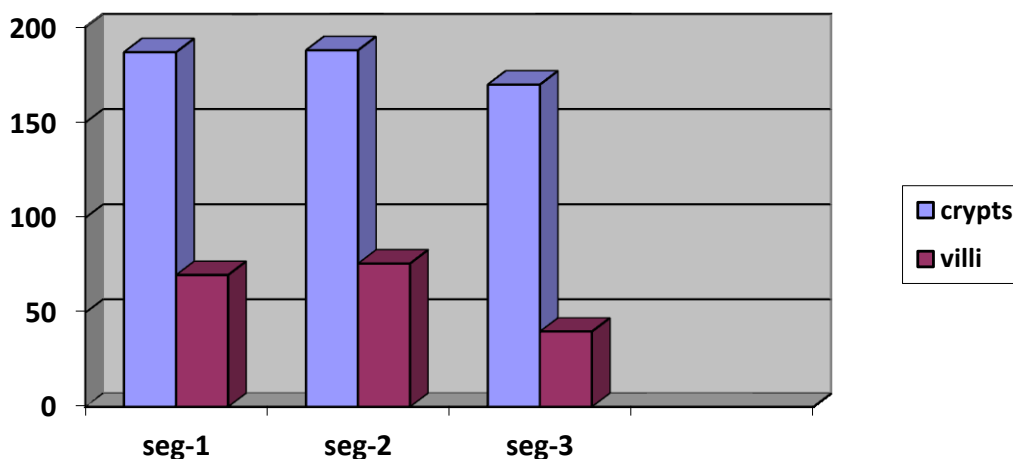
volumetric density of mast cells as well as their numerical density in the lamina propria of jejunum villi are significantly higher than that of the ileum ( $p < 0.01$ ). Similarly mast cells of the crypts were highly different than those in the villi ( $p < 0.005$ ).

The mean values of MMCs numbers and their distributions in control animals were consistent with those of the previously published data.<sup>7</sup>

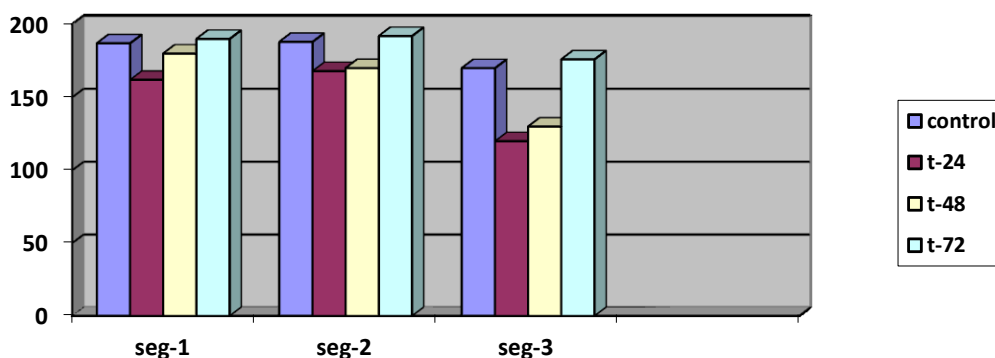
In the treated rats the numbers of the mast cells were significantly reduced after 24 hours in general, while an increase in values of these cells was found after 48 hours and exceeded the normal values of control animals after 72 hours.

**Table: The mean values of mucosal mast cells per square millimeter of connective tissues of the entire small intestine of control and Prednisolone treated rats;**

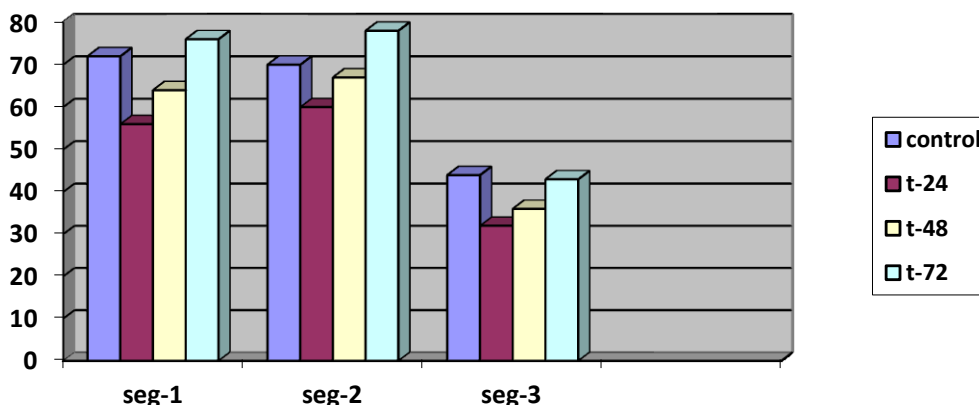
	control	treated	treated	treated
		24hrs	48hrs	72hrs
Villi	62000	50000	55000	65000
Crypts	181000	150000	160000	186000



**Fig. 1: The normal distribution of MMCs of control rats along the small intestine**



**Fig. 2: The mean values of the crypt MMCs numbers in the three small intestinal segments of control and treated rats after 24, 48 and 72 hours after the treatment.**



**Fig. 3: The mean values of the villous MMCs numbers in the three small intestinal segments of treated rats after 24, 48 and 72 hours after the last prednisolone dose.**

Through the 5-8 $\mu$  thick sections, MMCs were counted, most of which showed, complete profiles with centrally located and sectioned nuclei. These were found throughout the lamina propria of the small intestine.

These counts showed the sensitivity of MMCs to glucocorticoids as they depleted the numerical density of these cells during the 24 hours following the drug injection. In general, the numbers of mast cells in the lamina propria around the crypts exceeded those in the villous lamina propria. The counts, in treated animals, seemed to be closer to the normal values found in control animals after 48 hours, whereas higher values were recorded after 72 hours.

The study has demonstrated that the drug induction to normal animals caused depletion of the MMCs of rats. Similar results were indicating the inhibitory effects of cortisone on blood lymphocytes few hours after the injection of the drug.<sup>8</sup> The reduction in the circulating immunocompetent cells was explained in part by the immediate migration of lymphocytes from the blood stream caused by high levels of glucocorticoids. These cells return to the circulation on the drop of these hormones.<sup>9</sup> Hydrocortisone administration slows down the synthesis activity in many tissues reducing the numbers of some immunoresponsive cells (as eosinophils, macrophages and lymphocytes) due to the inhibition of proliferation through the reduction of certain growth factors such as Transforming Growth Factor  $\beta$  I and II (TGF $\beta$ I&II). In addition, downregulation of growth factor signaling pathways leads to abnormal cell proliferation.<sup>10</sup> Having

differential regulations of growth factor isomers tending to be affected by the differences in the functional and the structural aspects of these cells and consequently their response to glucocorticoids. Lymphocytes with fc receptors for IgM which is significantly reduced by hydrocortisone while those with fc receptors for IgG are not altered. The lymphocytes and mast cells share some histochemical and staining characteristics and both respond to the hydrocortisone in a similar manner. Our findings in both types of cells are consistent with the results of other studies.

In mast cells, IgE is produced by B-cells (the antibody-producing cells of the immune system). IgE molecules, like all antibodies, are specific to one particular antigen. In allergic reactions, mast cells remain inactive until an allergen binds to IgE.

Dexamethasone was found to reduce the interleukin 4 leading to the inhibition of immunoglobulin E production and interleukin 5 through lowering the production of IL4 & IL5mRNA,<sup>11</sup> (Sewell, Lyndee, phanides, kinder, Russell and Ludowyke; 1997), Furthermore it suppresses fc epsilon in mast cells.<sup>12</sup>

Mast cells are different in different tissues and their responses to the injected drug refers to the diversity in their content of tryptase and alpha protease which vary in different physiological and pathological conditions.<sup>13</sup> Other workers found that prednisolone inhibit the mast cell activation suggesting the success of the ability of glucocorticoids in the treatment of allergic

conditions due in part to their ability to inhibit mediators release and cytokine secretion. Glucocorticoids reduce IL3 dependent mast cell proliferation<sup>14</sup> by inhibiting their receptor expression. Mast cell granules carry a variety of bioactive chemicals. These granules have been found to be transferred to adjacent cells of the immune system and neurons via transgranulation via their pseudopodia. Glucocorticoids have the capacity to dramatically reduce the manifestations of inflammation. This due to their profound effects on the concentration, distribution, and function of peripheral leukocytes

#### References:

1. Sawicki, W., Bridges, J. B., Mughal, M. A. and Zoubi, S.A. (1984): Intestine associated lymphoid system. *Garyounis Medical Journal*, 7; 187.
2. Taz, J. and Bernolsen, R. G.; (1977); Does heparin occur in mucosal mast cells of rat? *Journal of Histochemistry and cytochemistry*, 25:1058.
3. Mughal MA, Zoubi SA, and Sawicki W. (1985): Simple and modified method of staining mucosal mast cells and intraepithelial lymphocytes. *Garyounis Medical Journal*, 1985;8:31.
4. Cupps, T. R. and Fauci, A. S. (1982); Corticosteroid Mediated Immunoregulation in man, *Immunology Review* 65:133.
5. Berend, O., Ineke J. M., Peter T. A., Schlleken and Chris, J. V. (1987); Concentration-dependent effects of prednisolone on lymphocyte subsets and mixed lymphocyte culture in humans. *The journal of Pharmacology and experimental therapeutics*. 243;716.
6. Mayerhofer, G; (1980) Fixation and staining of granules in mucosal mast cells and intraepithelial lymphocytes, with special reference to the relationship between acid glucosaminoglycans in the two cell types. *Histochemistry Journal*, 12:513.
7. Mughal, M A, Zubi, S A, Strojny, P & Sawicki, W (1988); Stereological analysis of mucosal mast cell numbers in the rat intestine. *Garyounis Medical Journal* 11 1-2
8. Haynes, B. F. and Fauci, A. F. (1978); The differential effect of in vivo hydrocortisone on blood T-lymphocytes. *Journal of clinical investigations*; 62 (3),
9. Hassig, A. Kremer, H. Lanka, S. Liang, W. and Stampfi, K. (1998) 15 years of Aids, Home Pages- Internet publications.
10. Daniel, O. Bianco, B. Elian, B. and Gama, P. (2006) Glucocorticoids induce differential expression of TGF isoforms. *Regulatory Peptides*, 135, 1-2, 17-22
11. Sewell, A.; Lyndee L. phanides, S.; kinder, S. Russell I and Ludowyke. (1997) :Induction of interleukin - 4 and interleukin - 5 Expression in mast cells is inhibited by Glucocorticoids clinical and Diagnostic laboratory immunology. P.18-23. Vol. 5, No. 1.
12. Yamaguchi, M.; Hirai, k.; komiya, A. Miyamasu, M.; Furmoto, Y. Teshima, R. and Ohata, K. (2001): Regulation of mouse mast cell surface Fc epsilon RI expression by dexamethasone, *Int. Immunol*; 13(7):843-51.
13. Hogan, A. D. and Schwartz, L. B. (1997); Markers of mast cell degranulation. *Methods*, 13 (1);43-52
14. Sakai, H.; Toyota, N.; Ito F, Takahashi, H. Hashimoto, Y. and Iziuka H. (1999) Glucocorticoids inhibit proliferation and adhesion of the IL-3- dependent mast cell line. *Arch. Dermatol. Res*. 291(4):224-31.

#### Conclusion:

MMC's numbers were decreased through the Prednisolone treatment but this effect was reversible and is consistent with most of the previous findings. Other values may fluctuate according to many circumstances such as species, age, and nutritional status, type of tissue, or may be due to technical differences in tissue sampling and morphometry. Histochemical and immunocytochemical studies should be carried out to clarify further estimations, rule and interrelations of the MMCs and other cell types with the glucocorticoid effects in the gastrointestinal tract.